

Cytological Analysis of Cervical Papanicolaou Smears in a Tertiary Hospital in Calabar, Nigeria

Godstime I. Irabor^{1*}, Dominic Akpan², Ejemen G. Aigbe³, Gift E. Irabor⁴, Omoruyi A. Kenneth⁵, Ayodele J. Omotoso⁵, Edoise Isiwele⁶ and Iyere Irabor⁷

¹*Department of Pathology, Saba University School of Medicine, Saba, Netherlands.*

²*Department of Laboratory Medicine and Pathobiology, University of Toronto, Ontario, Canada.*

³*Irrua Specialist Teaching Hospital, Irrua, Nigeria.*

⁴*Faculty of Education, Ambrose Alli University, Ekpoma, Nigeria.*

⁵*Department of Pathology, University of Calabar Teaching Hospital, Calabar, Nigeria.*

⁶*Department of Surgery, University Calabar Teaching Hospital, Calabar, Nigeria.*

⁷*Institute of Public Analyst of Nigeria, Lagos, Nigeria.*

Authors' contributions

This work was carried out in collaboration between all authors. Authors GII and DA designed the study, performed the statistical analysis, wrote the protocol and wrote the first draft of the manuscript. Authors GEI, EGA, OAK and AJO managed the analyses of the study. Authors EI and II managed the literature searches. All authors read and approved the final manuscript.

Article Information

DOI: 10.9734/IRJO/2018/44418

Editor(s):

(1) Dr. Guy-Armel Bouda, Department of Clinical pharmacy, School of Basic Medicine and Clinical Pharmacy, China Pharmaceutical University, China.

Reviewers:

(1) Sandeep Singh, Academic Medical Center, Netherlands.

(2) Diana C. Tapia-Pancardo, National Autonomous University of México, México.

(3) Shereen Ahmed Ahmed Qalawa, Port-Said University, Egypt.

Complete Peer review History: <http://www.sciencedomain.org/review-history/26772>

Original Research Article

Received 14 July 2018
Accepted 04 October 2018
Published 23 October 2018

ABSTRACT

Background: Cancer of the cervix is caused by a virus called human papillomavirus (HPV) which infects the uterine cervical epithelium. The Papanicolaou smear is a type of exfoliative cytology. Exfoliative cytology is the study of cells desquamated or shed from the body surfaces (e.g. cervix) or lesions for the purpose of diagnosis or cytological analysis.

Aim: To do a cytological analysis of cervical Papanicolaou smears in a tertiary hospital in Calabar, Nigeria.

Study Design: Retrospective prevalence study design.

Study Place and Duration: The study was done at the Department of Pathology, University of Calabar Teaching Hospital, Calabar on cervical smear analyzed between January, 2011 and December, 2013.

Methodology: This is a retrospective prevalence study of the entire cervical smear (conventional smears) analyzed at the Department of Pathology, University of Calabar Teaching Hospital from January 2011 to December 2013. The relevant information including sociodemographic data, clinical information and diagnosis of the subjects were obtained from the medical records/cytology register and the information was analyzed.

Results: A total of 525 Pap smear were analyzed during the study period. The age range of the patient is between 18 years and 90 years. The mean age of the subjects is 43 years \pm 3 SD. The age group with the highest prevalence is the 41-50 years group making up 32% of the subjects followed by 31- 40 years with a prevalence of 29.5%. The group with the lowest prevalence is the 81 – 90 years with a prevalence of 0.6%. The diagnosis with NILM (negative for intraepithelial lesion or malignancy) make up 83% of the total diagnosis, followed by high grade intraepithelial lesion – HSIL (6%), low-grade squamous intraepithelial lesion – LSIL (6%), Inadequate (4%) and atypical squamous cell of undetermined significance - ASCUS (1%).

Conclusion: Pap smear results negative for intraepithelial lesion or malignancy (NILM) was the commonest diagnosis among the patients who presented for cervical cancer screening. Having a larger number of females without any cervical lesions come for cervical cancer screening is a welcome development that would enable the detection and appropriate treatment of intraepithelial lesion if they develop.

Keywords: Cervical; cancer; malignancy; intraepithelial; lesion; cytology.

1. INTRODUCTION

There are more than 500,000 cases of cervical cancer each year and over 250,000 women die from the disease yearly [1]. Cervical cancer is the commonest gynaecological malignancy. Cancer of the cervix is caused by a virus called human papillomavirus (HPV) which infects the uterine cervical epithelium. The Papanicolaou smear is used for cervical cancer screening and it is a type of exfoliative cytology. Exfoliative cytology is the study of cells desquamated or shed from the body surfaces (e.g. cervix) or lesions for the purpose of diagnosis or cytological analysis [2] These cells may be obtained by procedures such as smear, aspiration, washing and scraping [2,3]. In this test cervical epithelial cells are collected from the cervix with the use of a cervical brush or Ayre's Spatula, a smear is made on a slide, stained and analyzed [3]. This test helps to screen for the presence of premalignant and malignant lesions in the uterine cervix. If a Pap smear detects a premalignant lesion or cervical cancer in its early stages, it is possible to treat and cure the disease before it has a chance to spread [4].

Premalignant changes or cancer of the cervix is caused by a virus called human papillomavirus (HPV) which infects the uterine cervical epithelium [5]. Some types of HPV cause mostly genital warts such as HPV 6 and 11, and some

types of HPV (such as types 16 and 18) can cause cancer. Most times persons who are infected with HPV are asymptomatic, but they can spread the virus to others. HPV that infect the cervical epithelium is spread through sexual contact with an infected person [6]. The doctor uses an Ayres spatula or small brush to collect cells from the epithelial surface of the cervix. The specimen is processed and analyzed for the presence of viral cytopathic changes.

Because the virus is so common, most people acquire the virus when they resume sexual intercourse but 80% of these people clear the infection within two years of the onset of the disease [7]. When this infection persists, there is premalignant lesion which develops in the cervical epithelium and may transform into a malignant lesion with time.

The Pap test remains the one of the best ways to screen sexually active women for cervical cancer. Exfoliated cells are gently scraped from the cervix and are sent to a cytopathological laboratory for proper evaluation [8].

Conventional cytology aims at detecting the presence of high-risk HPV infection in the uterine cervical epithelium is with Papanicolaou (Pap) smear. This method of diagnosing HPV infection was introduced in 1949 and named after George Papanicolaou before the cause of cervical cancer

was discovered in 1976 by Hausen. This has helped reduce the incidence of cervical cancer significantly especially in countries with a well organized cervical screening program like the United States of America [9-18]. The cytopathic changes caused by high risk HPV infection in the cervical epithelial cells like those in the transformation zone can be detected using this tool [17-21].

Monolayer cytology is a new method of processing specimen for Papanicolaou smear. Studies have shown that it has a higher sensitivity when compared to the conventional method. It reduces the number of false-negative results. The specimen is usually collected with a cervical brush which provides more adequate epithelial cells almost twice that of other collection devices. The specimens collected are preserved immediately. The methods that create this uniform monolayer prevents drying artefacts, removes contaminating mucus, bacteria, yeast, proteins and red blood cells [22,23,24,25]. The two methods of liquid-based cytology include: Thinprep system where the cells preserved in buffered alcohol preservative are filtered and the cells deposited on the filter paper are transferred to a slide by touching the slide with the filter paper and SurePath system. The cells are collected with a brush/spatula and the cells dropped into a surepath vial the specimen is collected in ethanol-based preservative. Gravity dispersion is utilized to sediment the enriched cellular specimen onto an adhesive-coated slide within a circle of 13 mm diameter.

Recently, two computerised systems have been recently introduced. They are AutoPap and PapNet. These systems are made to ensure an objective analysis of Pap smear. Abnormal cells are displayed on the screen for review and analysis [22,24].

The reporting system for Pap smear is the Bethesda system first introduced in 1988, amended in 1991, updated in 1999 and modified in 2001.

Bethesda system 2001 classifies squamous cell abnormalities into four categories:

- ASC (Atypical squamous cells)
 - ASC-US (atypical squamous cell of undetermined significance): here the lesion has cellular abnormalities suggestive of SIL.
 - ASC-H (atypical squamous cells cannot exclude high SIL).

- LSIL (low grade squamous intraepithelial lesions).
- HSIL (high-grade squamous intraepithelial lesion).
- Squamous cell carcinoma.

When a Pap smear is abnormal (presence of squamous intraepithelial lesion), 3% acetic acid is applied to the cervix and it is examined using a bright filtered light with the aid of a colposcope following which a colposcopy-directed biopsy could be done. Areas of dysplasia or carcinoma can be visualised as areas of acetowhitening and abnormal vascular patterns. Similarly, Lugol's iodine could be applied to the cervix. This can be visualized as mahogany brown or black appearance in normal areas of the cervical epithelium with intracellular glycogen and yellow in areas of dysplasia or carcinoma composed of cells lacking intracellular glycogen. A biopsy is taken from these areas and analyzed.

The aim of this study is to do a cytological analysis of cervical Papanicolaou smears in a tertiary hospital in Calabar, Nigeria.

2. METHODOLOGY

This is a retrospective prevalence study of the entire cervical smear analyzed at the Department of Pathology, University of Calabar Teaching Hospital from January 2011 to December 2013. The relevant information including sociodemographic data, clinical information and diagnosis of the subjects were obtained from the medical records/cytology register and the information was analyzed using Microsoft Excel 2010. The diagnosis is categorized using the Bethesda system of classification (Appendix A).

The data obtained from this study were analyzed using simple inferential statistics.

Inclusion criteria: All the Pap smear samples obtained and analyzed between January 2011 and December 2013 at the Department of Pathology, University of Calabar Teaching Hospital, Calabar, Nigeria.

3. RESULTS

3.1 General Findings

A total of 525 Pap smear were analyzed in the Department of Pathology, University of Calabar Teaching Hospital, Calabar, Nigeria during the 3-year-study period from January 2011 to

December 2013. The age range of the patient is between 18 years and 90 years. The mean age (mean ± SD) of the subjects is 43 ± 3 years.

3.2 Sociodemographic Data

The age group with the highest prevalence is the 41-50 years group making up 32% of the subjects followed by 31- 40 years with a prevalence of 29.5%. The group with the lowest prevalence is the 81 – 90 years with a prevalence of 0.6%.

4. DISCUSSION

Cervical cancer is a huge public health problem worldwide. Organized cervical cancer screening

has been helpful in reducing the incidence of cervical cancer worldwide [18].

In this study, the age range of the subjects was female in their reproductive age and post-menopausal women between 18 and 90 years of age. This forms the major group of the females who are at risk of developing premalignant and malignant cervical lesions [19]. The mean age (years + SD) of the subjects is 43 ± 3years which is consistent with findings by Gage et al. [21] Female patients within the highest risk age group 41-50 years has the highest proportion of the patients that were screened within the study period and this correspond to the peak age of cervical cancer [24]. This might be due to the increase in urge for physicians to send patients for cervical cancer screening when their age is within the high-risk group.

Table 1. Age distribution of the subjects

S/N	Age groups (yrs)	Frequency	Prevalence (%)
1	11-20	14	2.7
2	21-30	57	10.9
3	31-40	155	29.5
4	41-50	168	32
5	51-60	80	15.2
6	61-70	33	6.3
7	71-80	15	2.9
8	81-90	3	0.6
Total		525	100

Age range: 18-90
Mean age (mean±SD): 43± 3 years

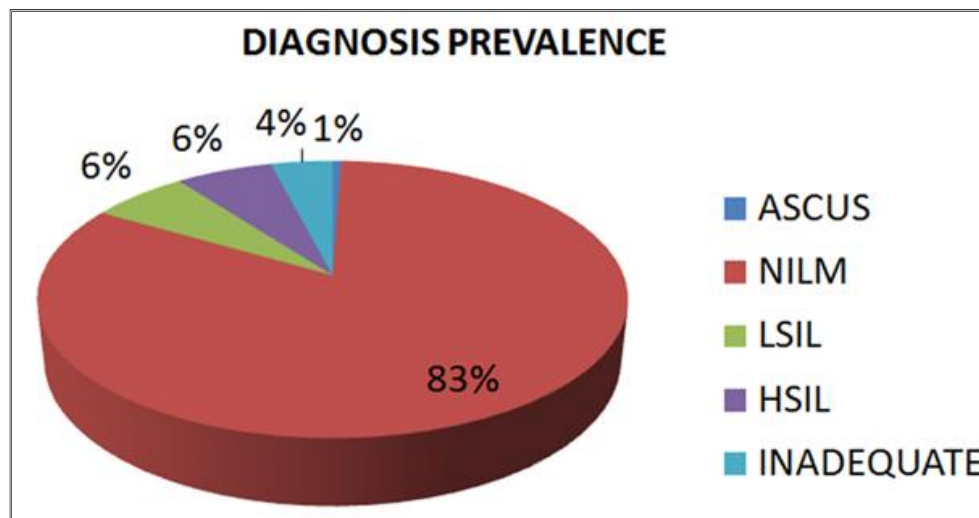


Fig. 1. Shows each diagnosis prevalence

ASCUS – Atypical squamous cell of unknown significance, NILM- Negative for intraepithelial lesion or malignancy, LSIL – Low grade squamous intraepithelial lesion, HSIL – High grade squamous intraepithelial lesion, INADEQUATE- Inadequate sample

Table 2. Age distribution for the diagnosis

Age	ASCUS	NILM	HSIL	LSIL	Inadequate	Total
11-20		12(2.7%)			2(9.5%)	14
21-30		45(10.4%)		9(27.3%)	3(12.3%)	57
31-40	1(33.3%)	138(31.7%)	3(9.1%)	6(18.2%)	7(33.3%)	155
41-50	2(66.7%)	135(31.0%)	18(54.6%)	7(21.2%)	6(28.6%)	168
51-60		63(14.5%)	9(27.3%)	5(15.2%)	3(12.3%)	80
61-70		27(6.2%)		6(18.2%)		33
71-80		12(2.8%)	3(9.1%)			15
81-90		3(0.7%)				3
Total	3	435	33	33	21	525

ASCUS – Atypical squamous cell of undetermined significance, NILM- Negative for intraepithelial lesion or malignancy, LSIL – Low grade squamous intraepithelial lesion, HSIL – High grade squamous intraepithelial lesion, Inadequate- Inadequate sample

The prevalence of each pap smear diagnosis is shown in Fig. 1. The diagnosis with the highest prevalence is negative for intraepithelial lesion/malignancy (NILM). NILM made up 83% of the diagnosis of Pap smear in the subjects within the study period. This finding is consistent with findings from a study by Omotoso et al. [26]. This is also consistent with findings by Bamanikar et al with a NILM prevalence of 88.9% and findings by Ranabhat et al and Atilgan et al. [27,28,29]. This may be as a result of increasing public education awareness of cervical cancer and its screening. More and more women appear to now present themselves for cervical cancer screening in Nigeria. The prevalence of LSIL and HSIL were the same (6% each) both accounting for 12% of the diagnosis made in these patients. This is generally higher than that obtained from the study by Bamanikar et al and that from a study by Magdy et al. [30]. On the other hand, this finding for LSIL is consistent with that from the study by to that by Omotoso et al. [26] Also, the prevalence of HSIL in this study is higher that from the study by Omotoso et al. [26]. The study by Omotoso et al recruited patients attending a clinic for various reasons while this study analyzed results of the cervical smear of the patients whose samples were analyzed in the department of Pathology, University of Calabar Teaching Hospital, within the study period. However, the proportion of ASCUS diagnosis was 1% which is slightly lower than that from the study by Bamanikar et al with an ASCUS prevalence of 2.3%. However the overall prevalence of abnormal cytological findings in this Pap smear studied is 13% which is consistent with the findings from studies from other parts of the world [31,32]. The proportion of patients with inadequate specimen is 4% which constitutes one of the least diagnosis made from Pap smear and for conventional smears used in

this study, a lot of factors are contributory to making a sample inadequate including excess of inflammatory cells which obscure the ability of the pathologist to make a reasonable assessment of the smears. This value is slightly lower than that from the study by Bamanikar et al. [27] with a prevalence of 5.71%. More effort has to be put into public health education about cervical cancer screening in order to increase the number of these lesions that can be caught early and treated [33,34]. The government of countries in sub-Saharan Africa may need to incorporate the Gardasil-9 into their national immunization program. This would go a long way in protecting women from high-risk HPV infections from HPV testing but it is not yet a part of the cervical screening program in the study area [31,33].

5. CONCLUSION

Pap smear results negative for intraepithelial lesion or malignancy (NILM) was the commonest diagnosis among the patients who presented for cervical cancer screening. Having a larger number of females without any cervical lesions come for cervical cancer screening is a welcome development that would enable the detection and appropriate treatment of intraepithelial lesion if they develop. As the public becomes more aware of cervical cancer, more persons would present themselves for cervical cancer screening and this would go a long way in reducing the incidence of cervical cancer.

6. RECOMMENDATIONS

The introduction of human papillomavirus co-testing would be needed as part of the cervical screening program in sub-Saharan Africa in order to reduce the incidence of cervical cancer to the barest minimum.

CONSENT AND ETHICAL APPROVAL

It is not applicable.

COMPETING INTERESTS

Authors have declared that no competing interests exist.

REFERENCES

1. Ferlay J, Shin HR, Bray F, Forman D, Mathers C. Estimates of worldwide burden of cancer in 2008: GLOBOCAN. *Int J Cancer*. 2008;127:2893-2917.
2. Exfoliative cytology, medical dictionary, The free dictionary. Available:<https://medical-dictionary.thefreedictionary.com/exfoliative+cytology> (Accessed on 5/7/2018)
3. Devices for collection of cervical cellular samples, Guidelines for taking cellular samples, Collecting and processing cellular samples from the cervix, cervical cytology. Available:<https://www.eurocytology.eu/en/course/1119> (Accessed on 5/7/2018)
4. Burd EM. Human papillomavirus and cervical cancer. *Clinical Microbiology Reviews*. 2003;16(1):1-17. DOI: 10.1128/CMR.16.1.1-17.2003
5. Centre for disease control, Human Papillomavirus. Available:<https://www.cdc.gov/vaccines/pubs/pinkbook/downloads/hpv.pdf> (Accessed on 6/7/2018)
6. Dixit R, Bhavsar C, Marfatia YS. Laboratory diagnosis of human papillomavirus virus infection in female genital tract. *Indian Journal of Sexually Transmitted Diseases*. 2011;32(1):50-52. DOI: 10.4103/0253-7184.81257
7. Brown DR, Shew ML, Qadadri B, Neptune N, Vargas M, Tu W, et al. A longitudinal study of genital human papillomavirus infection in a cohort of closely followed adolescent women. *J Infect Dis*. 2005; 191:182–92. [PMC free article] [PubMed]
8. Saslow D, Runowics CD, Solomon D, Smith RA, Eyre HJ, Cohen C. American cancer society guideline for the early detection of cervical neoplasia and cancer. *Cancer Journal of Clinicians*. 2009;53(2): 126-7.
9. Gakidou E, Nodhagen S, Obermeyer Z. Coverage of cervical cancer screening in 57 countries: Low average levels and large inequalities. *The Global Challenges of Noncommunicable Diseases*. *PLOS/Medicine*. 2008;5(6):132-34. DOI: 10.1371/journal.pmed.0050132 (Cited on 19/03/14).
10. Hausen HZ. Papillomavirus causing cancer: Evasion from host – control in early events in carcinogenesis. *J Natl Cancer Inst* 2000; 92: 690-8.
11. Human papillomavirus vaccine, vaccine ingredients and manufacturers information, ProCon.Org. Available:<http://vaccines.procon.org> (Cited on 20/03/14)
12. Sharbatadaran M. Sensitivity and specificity of p16 immunohistochemistry in diagnosis of dysplastic neoplastic changes in cervix. *Babol Univ Med Sci*. 2009; 11(1):1-12.
13. Eehalt D, Lener B, Pircher H, Dreier K, Pfister H, Kaufmann AM, et al. High risk Human papillomavirus E7 oncoprotein in cervical squamous cell carcinoma. *Clin Cancer Res*. 2007;13(23):7067-69.
14. Stoler MH, Mills ES, Gersell DJ, Walker AN. Small cell neuroendocrine carcinoma of the cervix. A human papillomavirus type-18 associated cancer. *Am J Surg Pathol*. J. 1991;15(1):28-32.
15. Ciaponi A, Bardach A, Glujovsky D, Gibbons L, Alejandra M. Type specific Human papillomavirus prevalence in cervical cancer and high-grade lesions in latin America and Caribbeans: Systematic review and meta-analysis. *PLOS/One*; 2011. DOI: 10.1371/Journal.pone.0025493 (Cited on 18/ 03/14).
16. Chichareon S, Herrero R, Muñoz N, Bosch FX, Jacobs MV, Deacon J, et al. Risk factors for cervical cancer in Thailand: A case control. *J Natl Cancer Inst*. 1998;90: 50-7.
17. Sitas F, Parkin M, Chirenje Z, Stein L, Mqoqi N, Wabinga H. *Cancers*. In: Jamison DT, Feachem RG, Makgoba MW, Editors, *Disease and Mortality in Sub-Saharan Africa*. 2nd edition. Washington (DC): World Bank; 2006. Chapter 20. Available:<http://www.ncbi.nlm.nih.gov/books/NBK2293> (Cited on 12/06/14).

18. Whitlock EP, Vesco KK, Eder M. Liquid-based cytology and human papillomavirus testing to screen for cervical cancer: a systematic review for the U.S. Preventive Services Task Force. *Ann Intern Med.* 2011;155:687- 697.
19. Mohan H. Cervix: Female genital tract, Pathology quick review and MCQ. Third edition Indian: Jaypee. 2000;603–627.
20. Saraiya M, Steben M, Watson M, Markowitz L. Evolution of cervical screening and prevention in the United States and Canada: Implication for public health practitioners and clinician. *Preventive Medicine* 2013;57(5):426–433.
21. Gaje JC. The age specific prevalence of human papillomavirus and of cytological abnormalities in rural Nigeria: Implication for screening and treat-strategy. *Int J Cancer.* 2011;130(9):211-7.
22. Eileen MB. Human papillomavirus and cervical cancer. *Clin Microbiol Rev.* 2003; 16(1):1-17.
23. Solomon D, Davey D, Kurman R. The 2001 Bethesda system: Terminology for reporting results of cervical cytology. *JAMA.* 2002;287(16):2114-2189.
24. Posado EM, Kotz HL. Cervical cancer, In: Abraham J, Gulley J L, Allegra CJ (Editors) Bethesda handbook of clinical oncology, second edition. Lippincot, Williams and Wilkins. 2005;Chapter 5:248-260.
25. Omotoso AJ, Patience O, Irabor GI, Oshatuyi O, Nnenna W. Cervical smear analysis of women in Cross River State, Nigeria. *JABB.* 2017;16(2):1-5.
26. Ellenson LH, Pirong EC. Cervix: Premalignant and malignant neoplasm. In: Kumar V, Abbas AK, Fausto N, Aster JC (editors) *Pathologic basis of disease.* 8th Edition. Philadelphia: Elsevier. 2010;1018-1024.
27. Bamanikar SA, Baravkar DS, Chandanwale SS, Dapkekar P. Study of cervical Pap smear in a Tertiary Hospital, Indian Medical Gazette. 2014;250-54.
28. Ranabhat SK, Shrestha R, Tiwari M. Analysis of abnormal epithelial lesions in cervical Pap smears in Mid-Western Nepal. *Journal of Pathology of Nepal.* 2011;1:30-33.
29. Atilgan R, Celik A, Boztosun A, Ilter E, Ozercan TY. Evaluation of cervical cytological abnormalities in Turkish population. *Indian J Pathol Micr.* 2012; 55(1):52-55.
30. Magdy HB, Mohammed SM, Naema G, Souad O. Cytological pattern of cervical Papanicolaou smear in eastern region of Saudi Arabia. *J Cytol.* 2011;28(4): 173–177.
31. Turkish Cervical Cancer And Cervical Cytology Research Group: Prevalence of cervical cytological abnormalities in Turkey. *Int J Gynaecol Obstet.* 2009; 106:206-209.
32. Ghaith JE, Rizwana BS. Rate of Opportunistic Pap smear Screening and Patterns of Epithelial Cell Abnormalities in Pap Smears in Ajman, United Arab Emirates. *Sultan Qaboos Univ Med J.* 2012;12(4):473–478.
33. Irabor GI, Omotoso AJ, Isiwale EM, Nnoli MA, Omoruyi KA. Histopathological study of Cervical cancer specimen, University of Calabar Teaching Hospital, Calabar, Med. Res. Chron. 2017;4(5):582–90.
34. Singh S, Hussan S, Badaya S. Prospect of cytological cervical cancer screening in India: Exploring adjuvant approaches. *J Can Res Her.* 2017;12:389–91.

APPENDIX A

The 2001 Bethesda System

Interpretation/Result

Negative for Intraepithelial Lesion or Malignancy:

(When there is no cellular evidence of neoplasia, state this in the General Categorization above and/or in the Interpretation/Result section of the report, whether or not there are organisms or other non-neoplastic findings).

- Organisms:

Trichomonas vaginalis

Fungal organisms morphologically consistent with *Candida* spp

Shift in flora suggestive of bacterial vaginosis

Bacteria morphologically consistent with *Actinomyces* spp.

Cellular changes consistent with Herpes simplex virus

- Other Non Neoplastic Findings (Optional to report; list not inclusive):

Reactive cellular changes associated with

- Inflammation (includes typical repair)
- Radiation
- Intrauterine contraceptive device (IUD)

Glandular cells status post hysterectomy

Atrophy

Other

- Endometrial cells (in a woman \geq 40 years of age)

(Specify if 'negative for squamous intraepithelial lesion')

Epithelial Cell Abnormalities

- SQUAMOUS CELL

Atypical squamous cells

- of undetermined significance (ASC-US)
- cannot exclude HSIL (ASC-H)

Low grade squamous intraepithelial lesion (LSIL)
(encompassing: HPV/mild dysplasia/CIN 1)

High grade squamous intraepithelial lesion (HSIL)
(encompassing: moderate and severe dysplasia, CIS, CIN 2 and CIN 3)

- with features suspicious for invasion (if invasion is suspected)

Squamous cell carcinoma

- Glandular Cell

Atypical

- endocervical cells (not otherwise specified (NOS) or specify in comments),
- endometrial cells (NOS or specify in comments),
- glandular cells (NOS or specify in comments)

Atypical

- endocervical cells, favor neoplastic
- glandular cells, favor neoplastic

Endocervical adenocarcinoma *in situ*

Adenocarcinoma:

- endocervical
- endometrial
- extrauterine
- not otherwise specified (NOS)

Other Malignant Neoplasms: (Specify)

© 2018 Irabor et al.; This is an Open Access article distributed under the terms of the Creative Commons Attribution License (<http://creativecommons.org/licenses/by/4.0>), which permits unrestricted use, distribution, and reproduction in any medium, provided the original work is properly cited.

Peer-review history:
The peer review history for this paper can be accessed here:
<http://www.sciencedomain.org/review-history/26772>